

Circulation

JOURNAL OF THE AMERICAN HEART ASSOCIATION



The Long-QT Syndrome

Arthur J. Moss and Jennifer L. Robinson

Circulation 2002;105;784-786

DOI: 10.1161/hc0702.105125

Circulation is published by the American Heart Association, 7272 Greenville Avenue, Dallas, TX 75214
Copyright © 2002 American Heart Association. All rights reserved. Print ISSN: 0009-7322. Online
ISSN: 1524-4539

The online version of this article, along with updated information and services, is
located on the World Wide Web at:

<http://circ.ahajournals.org/cgi/content/full/105/7/784>

Subscriptions: Information about subscribing to *Circulation* is online at
<http://circ.ahajournals.org/subscriptions/>

Permissions: Permissions & Rights Desk, Lippincott Williams & Wilkins, 351 West Camden
Street, Baltimore, MD 21202-2436. Phone 410-5280-4050. Fax: 410-528-8550. Email:
journalpermissions@lww.com

Reprints: Information about reprints can be found online at
<http://www.lww.com/static/html/reprints.html>

THE CARDIOLOGY PATIENT PAGE

The Long-QT Syndrome

Arthur J. Moss, MD; Jennifer L. Robinson, MS

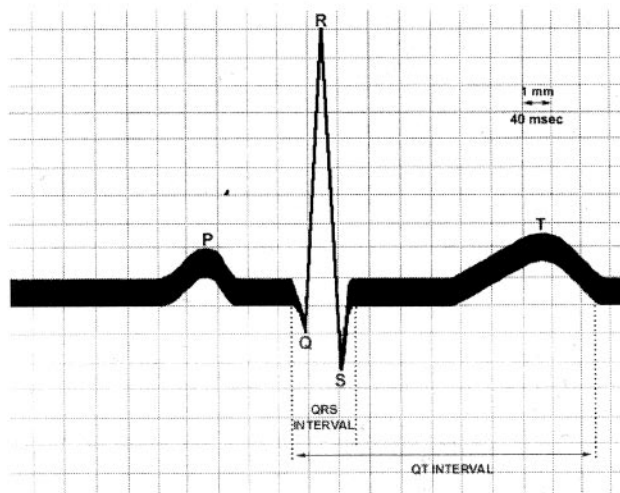
The heart is a pump that is stimulated by electrical signals to beat between about 50 to 180 times per minute, depending upon the individual's level of activity and emotional state. The heart itself is made up of millions of cells that generate repetitive sequences of electrical discharges (referred to in medicine as depolarization) and recharging (repolarization) that produce each heart beat. Electrical activity of the heart cells is produced by the synchronized movement of sodium, potassium, and calcium ions into and out of the cells.

Long-QT Syndrome

Long-QT Syndrome (LQTS) is a disorder of the electrical activity of the heart that can result in blackouts (fainting, also known as syncope) or sudden cardiac death. It occurs infrequently and is caused either by an inherited genetic condition (inherited form of LQTS) or by some prescription medications (acquired form of LQTS). QT refers to the interval on ECG between the beginning of the heart's electrical discharge through its electrical recovery (see Figure 1). Figure 1 illustrates how the QT interval is measured on the ECG.

Delayed electrical recovery within the heart can be associated with very dangerous, rapid, and chaotic heart rhythms (medical terms for these abnormal heart rhythms are ventricular tachycardia and torsades de pointes). When these disordered rhythms occur, the heart does not pump an adequate supply of blood to the brain; inadequate blood flow to the brain causes fainting episodes. The disorganized electrical activity of the heart can lead to sudden death. In many patients with LQTS, dangerous heart rhythms are triggered by abrupt arousal events such as emotional stress, unexpected

ECG - QT Interval



Schematic diagram of the electrical activity of one heart beat recorded by an ECG. The electrical discharge (depolarization) of the ventricle is represented by the QRS complex, with the T wave reflecting electrical recovery (repolarization). The QT is the time interval from the beginning of the QRS complex to the end of the T wave, and is generally less than 0.44 seconds in normal individuals. In subjects with the long-QT syndrome, the QT is usually longer than 0.44 seconds.

loud noises, or the vigorous physical activity associated with competitive sports.

What Are the Clinical Features of LQTS?

Individuals with LQTS generally appear to be in good health. The first manifestation of the disorder may be a fainting episode caused by a transient rapid heart rhythm. These fainting episodes may be a warning sign of a potentially life-threatening heart rhythm disorder and may be the forerunner of sudden death. In general, the individual has no forewarning of the faint and recovers quickly within a few minutes after loss of consciousness. Among those affected with the inherited form of LQTS, fainting events can occur at

From the Heart Research Follow-up Program of the Cardiology Unit of the Department of Medicine, University of Rochester Medical Center, Rochester, NY.

Correspondence to Arthur J. Moss, MD, Heart Research Follow-up Program, Box 653, University of Rochester Medical Center, Rochester, NY 14642. E-mail heartajm@heart.rochester.edu

(*Circulation*. 2002;105:784-786.)

© 2002 American Heart Association, Inc.

Circulation is available at <http://www.Circulationaha.org>

DOI: 10.1161/hc0702.105125

any age but are particularly frequent in the 10- to 20-year-old age group and in adult women.

It is not uncommon for a loss-of-consciousness episode to be mistaken for a seizure disorder. Thus, a fainting episode in a young, otherwise healthy individual requires a full medical examination including an electrocardiogram to evaluate the QT interval. The longer the QT interval on the ECG, the greater is the risk of developing a dangerous heart rhythm.

Certain medications can prolong the QT interval and produce the acquired form of QT prolongation with clinical manifestations similar to the inherited LQTS disorder (see www.torsades.org). Individuals with either the inherited form or acquired form of LQTS should know the names of these medications, avoid them, and consult with their cardiologists before beginning any prescribed medication.

Characteristics of the Long-QT Syndrome

- Infrequent (1 out of every 20 000 people)
- Rapid, chaotic heart rhythms
- Inherited abnormality in the electrical function of the heart but can also be caused by some prescription medicines
- Abnormal rhythms that cause fainting or loss of consciousness
- Increased risk for sudden death, especially in adolescence
- Greater risk of LQTS in adult women than men
- Deafness in certain inherited forms of LQTS

Genetic Aspects of Inherited Form LQTS

LQTS is a genetic condition that is transmitted from an affected parent to a child as a dominant disorder. If either parent has LQTS, each child has a 50 percent chance of inheriting the disorder.

Genetic mutations involving any 1 of 5 different genes are the primary cause of LQTS in the majority of patients. Four of these mutations result in reduced outflow of potassium ions from heart muscle cells during the electrical recovery process of each heart beat, and one mutation is associated with increased entry of sodium ions into the cells. These abnormal movements of the potassium and sodium ion across the heart cell membrane are responsible for QT prolongation and the electrical instability in LQTS. (For a more detailed discussion, go to www.sads.org and click on "LQTS Facts").

How Is LQTS Diagnosed?

Unexplained loss of consciousness is usually the first clue, with the LQTS diagnosis made if the QT interval is prolonged on the ECG.

Genetic testing is being used to identify the presence of LQTS gene mutations in selected individuals and families. Approximately 10% of individuals later confirmed by genetic testing to have LQTS have normal QT intervals on the resting ECG. Exercise testing and 24-hour heart rhythm recordings may clarify the diagnosis in some patients by finding intermittent QT prolongation and/or runs of rapid heart beats.

The family history may reveal unexplained sudden death in a young family member, a symptom of LQTS. Screening family members with an ECG will frequently identify those who previously had not exhibited symptoms or may never have passed out.

Clues to the Diagnosis of LQTS

- Clinical history: Fainting episodes especially with stress; congenital deafness
- Family history: Family member with confirmed LQTS; unexplained sudden death below age 30 years among immediate family members
- ECG findings: QT prolongation; low heart rate for age; unusual configurations to the T wave; documented episodes of rapid chaotic heart rhythms

Treatment for LQTS

The major treatment goal in LQTS is to prevent fainting and sudden death. Drugs that block the stimulating effects of adrenalin on the heart (β -blockers) are quite effective in preventing these events but do not provide absolute protection. An implanted device known as the implantable cardioverter defibrillator (ICD) can automatically diagnose and terminate fatal rapid heart rhythms (for a detailed explanation of how the ICD works see Reiffel and Dizon, *The Cardiology Patient Page*, "The Implantable Cardioverter-Defibrillator: Patient Perspective." *Circulation*. 2002. In press). These are life-saving devices for LQTS individuals who are at high risk for heart rhythm disorders. Electrophysiologists (pediatric and adult cardiologists who specialize in electrical disorders of the heart beat) should be involved in the medical care of the LQTS patient.

What Can Be Done to Prevent Fainting and Sudden Death in LQTS

If you or a family member has been diagnosed with LQTS:

- Be aware that abrupt arousal, sudden loud noises, stress, or vigorous physical activity can trigger dangerous heart rhythms. These environmental stimuli should be avoided. For example, the intensity of the ring from doorbells and phones should be reduced or eliminated and alarm clocks should be avoided. Participation in competitive sports is prohibited.
- A fainting episode is a warning sign that a dangerous heart rhythm has occurred, and your heart physician should be informed immediately of the event so that life-saving preventive therapy measures can be implemented.
- β -Blocker medication is very effective in this disorder, and you should be receiving this medication unless there is a specific contraindication. The dose of medication usually has to be increased in children as they grow older.
- Unnecessary medications, especially stimulants, weight reducing drugs, certain antibiotics, and over-the-counter drugs should be avoided. These medications and others can exacerbate the LQTS condition. Current information on drugs that should be avoided can be found on www.torsades.org.
- When a medication is prescribed for you, always inform your physician that you have LQTS and that medications known to prolong the QT interval should be avoided.
- You should check in regularly with a heart rhythm specialist (an electrophysiologist) in order to receive the very latest up-to-date preventive therapy.
- In selected patients, a device called an implantable cardioverter defibrillator (ICD) may be necessary. The options

for this therapy should be discussed with your heart specialist.

Further Information

For more information about LQTS, please consult one of the following sources:

- Moss AJ, Schwartz PI, Crampton RS, et al. The long-QT syndrome: prospective longitudinal study of 328 families. *Circulation*. 1991;84:1136–1144.

- Moss AF, Zareba W, Hall WJ, et al. Effectiveness and limitations of β -blocker therapy in congenital long-QT syndrome. *Circulation*. 2000;101:616–623.
- www.longqt.org
- www.sads.org
- www.torsades.org

Acknowledgments

The work has been supported in part by research grants HL-33843 and HL-51618 from the National Institutes of Health, Bethesda, Md.